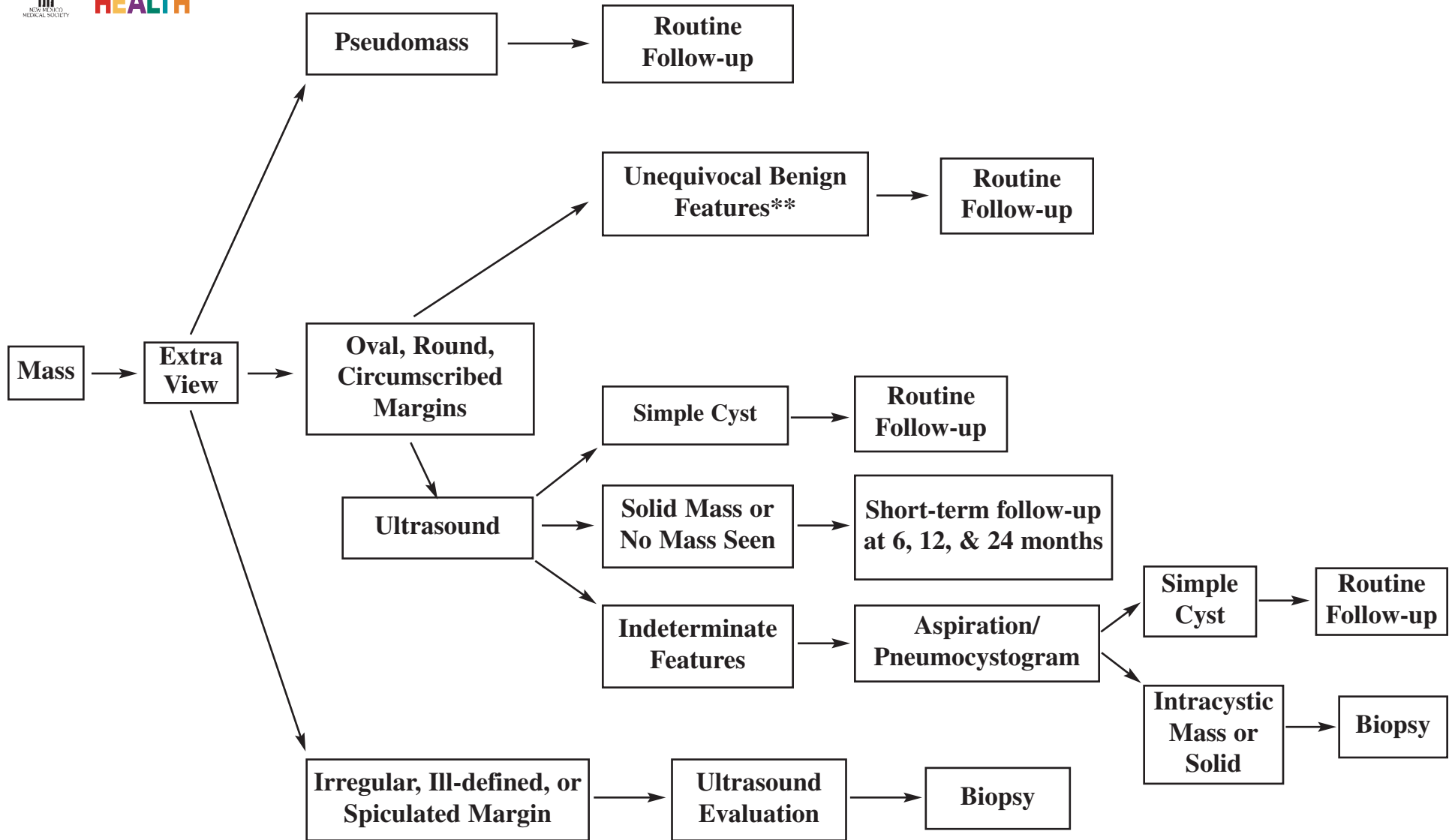


BREAST MASS EVALUATION: NON-PALPABLE, NON-CALCIFIED



**Fat-containing mass, multiple round circumscribed masses, typical degenerating fibroadenoma

Bassett LW. Imaging of breast masses. Radiologic Clinics of North America 2000;38:669-692.

Monsees BS. Evaluation of breast microcalcifications. Radiologic Clinics of North America 1995;33:1108-1121.